

ENDOCARDITIS, MYOCARDITIS AND PERICARDITIS

ENDOCARDITIS

Infective endocarditis is inflammatory disease of the endocardium, usually affecting valves, if not treated is leading to death.

-most frequent is bacterial, less frequent fungal (viral ???)

-mainly in older people, more men like women.

Non-infective is not so frequent.

Classification:

1. acute form
2. subacute form

Acute IE – etiologically Staphylococcus aureus, Streptococcus pyogenes, Neisseria etc.

-affecting usually healthy valves, causing metastatic lesions, proceed like sepsis.

Subacute IE – much more frequent, usually caused by streptococcal infection (Str. viridans or epidermidis) – affecting mainly valves damaged before infection. No metastatic deposits.

Etiological classification:

1. IE of native valves
2. IE of drugs abusers
3. IE of prosthetic valves

Risk classification:

1. **high risk** – prosthetic valves, aortic stenosis and insufficiency, opened ductus arteriosus Botali, A-V anastomoses, aortic coarctation, Marfan's syndrome, previous IE
2. **medium risk** – mitral stenosis, tricuspidal stenosis and insufficiency, hypertrophic cardiomyopathy, calcified aortic stenosis, Fallot tetralogy, mitral prolapse, mitral insufficiency
3. **low risk** - degenerative heart diseases, atrial defect – type septum secundum, luetic aortitis, pacemakers, aorto-coronary bypasses

Etiology and pathogenesis

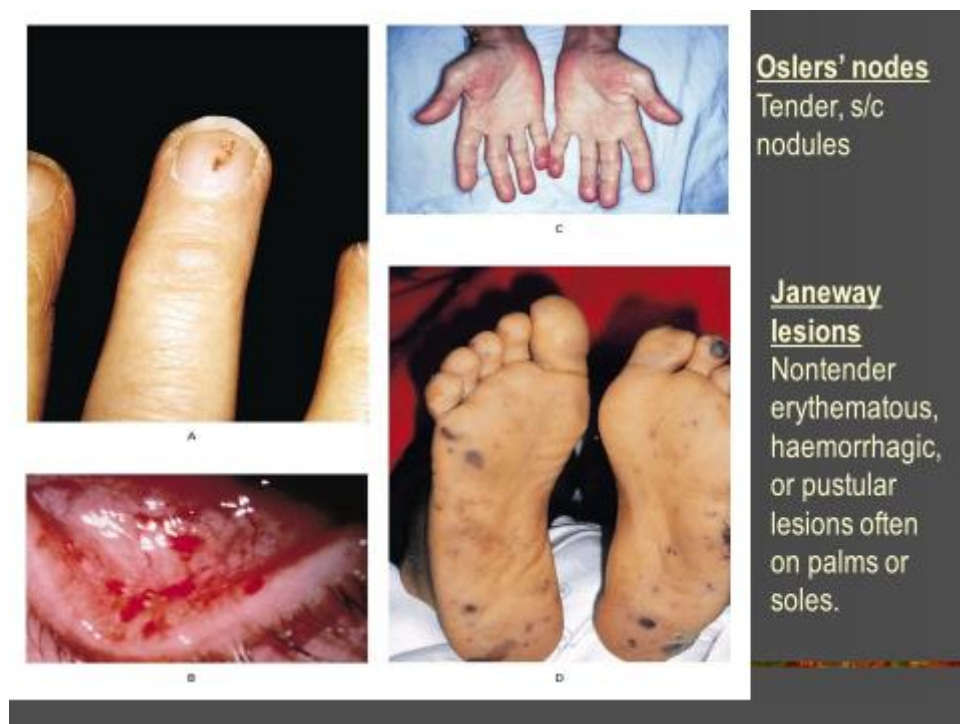
oropharyngeal infections, genitourinary, gastrointestinal or respiratory infections, history of instrumental procedures (endoscopy of respiratory or gastrointestinal tract), urological procedures, stomatological procedures, interruptions of gravidity.

formation of vegetations on the endocardium (fibrine, leucocytes and thrombocytes), more frequently on insufficient valves like stenotic ones, more frequent on aortic and mitral valve.

Clinical findings

dizziness, pain of joints, myalgia, loss of weight, fever.

skin – petechial bleedings, Osler's noduli (on palmar part of the fingers), colour of „caffee au lait „ – white coffee colour



heart – murmurs, dynamic changes of murmurs, heart failure

eyes - subconjunctival bleeding, retinal bleeding

enlargement of spleen

hepatomegaly

muscles and joints – arthritis, artralgiias, myalgias

Laboratory investigation

increased erythrocyte sedimentation – more than 100 per first hour

normocytic normochromatic anaemia

leukocytosis, increase of neutrophils

hypergamaglobulinaemia

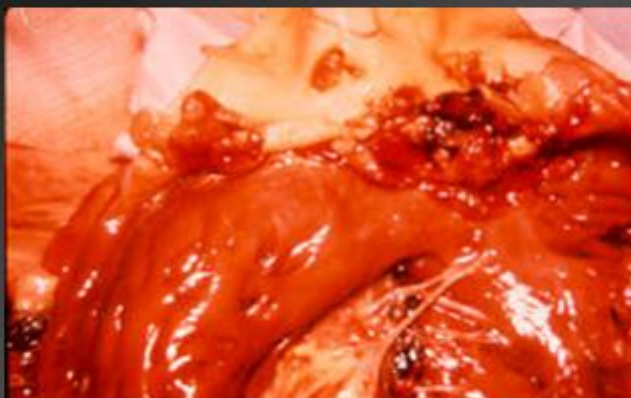positive hemoculture

renal findings – hematuria

increased inflammatory markers CRP, CIK

ECHO CG – vegetations

ENDOCARDITIS



Characteristic pathological lesion: vegetation,
composed of platelets, fibrin, microorganisms
and inflammatory cells.

Complications and prognosis

heart failure, glomerulonephritis, systemic embolisations (CNS, spleen, kidneys, lungs), valve destructions, arrhythmias

worse prognosis – IE of prosthetic valves, enterococcal IE, staph. aureus IE, worse left heart valves like right ones.

Therapy

very high doses of bactericidal ATB, duration at least 4 weeks

crystalline PNC 20 – 40 millions in four doses, combination with gentamycin (3 times 80mg) or streptomycin (1g two times daily)

cephalosporins (mefloxacin 4g/24 hod., cefalotin 8g/24 hod.)

oxacillin, vancomycin

surgical treatment – IE complicated with heart failure, persistent bacteriemia, fungal etiology, extravalvular complications, large vegetations, dehiscency of prosthetic valves

Prevention of IE

1. **before stomatological and respiratory procedures** (associated with bleeding), incisions, drainage – Amoxicillin 3grams 1 hour before procedure and 1,5 g 6 hours after procedure (if allergy is present erythromycin 1g 1 hour before procedure and 0,5 g 6 hours after procedure)
2. **before gastrointestinal and genitourinary procedures** – Amoxicillin 2g + gentamycin 80mg i.v. 30 minutes before procedure and 8 hours after procedure (if allergy on penicillin vancomycin 1g before procedure).

MYOCARDITIS

focal or diffuse inflammatory disease

Etiopathogenesis

viral infections – Coxsackie (50 %), echoviruses, influenza, hepatitis, infective mononucleosis, HIV

Viral (Most Common)

Adenovirus

Coxsackievirus, enterovirus

Cytomegalovirus

Parvovirus B19

Hepatitis C virus

Influenza virus

**Human immunodeficiency
virus**

Herpesvirus

Epstein-Barr virus

Mixed infections

bacterial – diphtheric, streptococcal, staphylococcal,
spirochetal – Lyme 's boreliosis
mycoplasmatic
protozoic – Chagas disease (Trypanosoma cruzi)
parasitary – (echinococcus, filariosis, trichinosis)

direct affection or indirect mechanism – immunoalterative

Clinical findings

ranging from **subclinical forms to fulminant forms** ending with heart failure or fatal arrhythmias

beginning – usually nonspecific symptoms - dizziness, cough, fever, arthralgias, myalgias, chest pain, breathlessness, tachycardia, various arrhythmias including sudden death

ECG - changes of ST-T, arrhythmias, bundle brunch blockade

ECHO CG – local disturbances of movement of the myocardial walls
(hypokinesia)

MRI

PCR , mollecular diagnostic techniques (viral genome)

cardiospecific enzymes – CK like in acute MI

virological examination

endomyocardial puncture

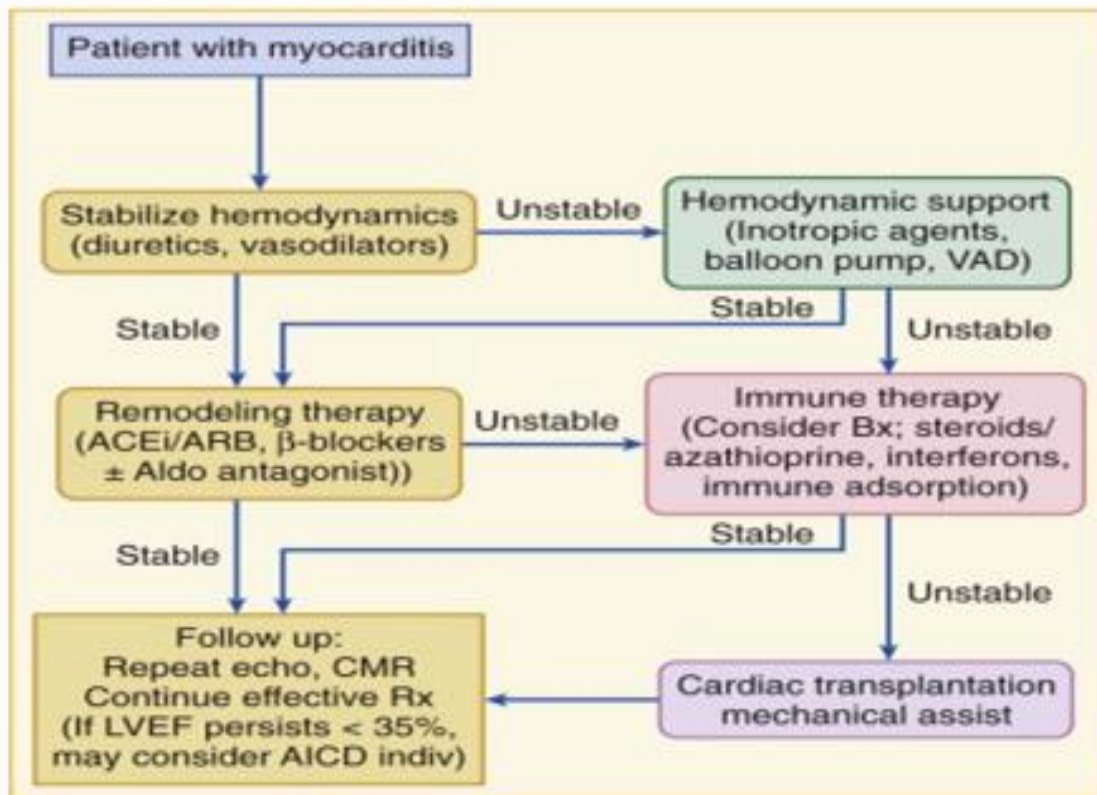
Treatment

rest, no exercise, ACE- inhibitors, ATB with broad spectrum of sensitivity (at least 3 weeks)

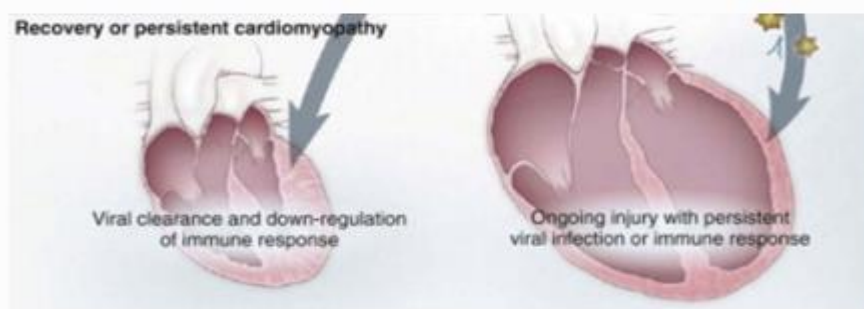
immunosuppression, interferon, immunomodulatory drugs

non steroidal antiinflammatory drugs

corticosteroids ?



Stage of recovery



PERICARDITIS

Acute pericarditis – inflammation of pericardium

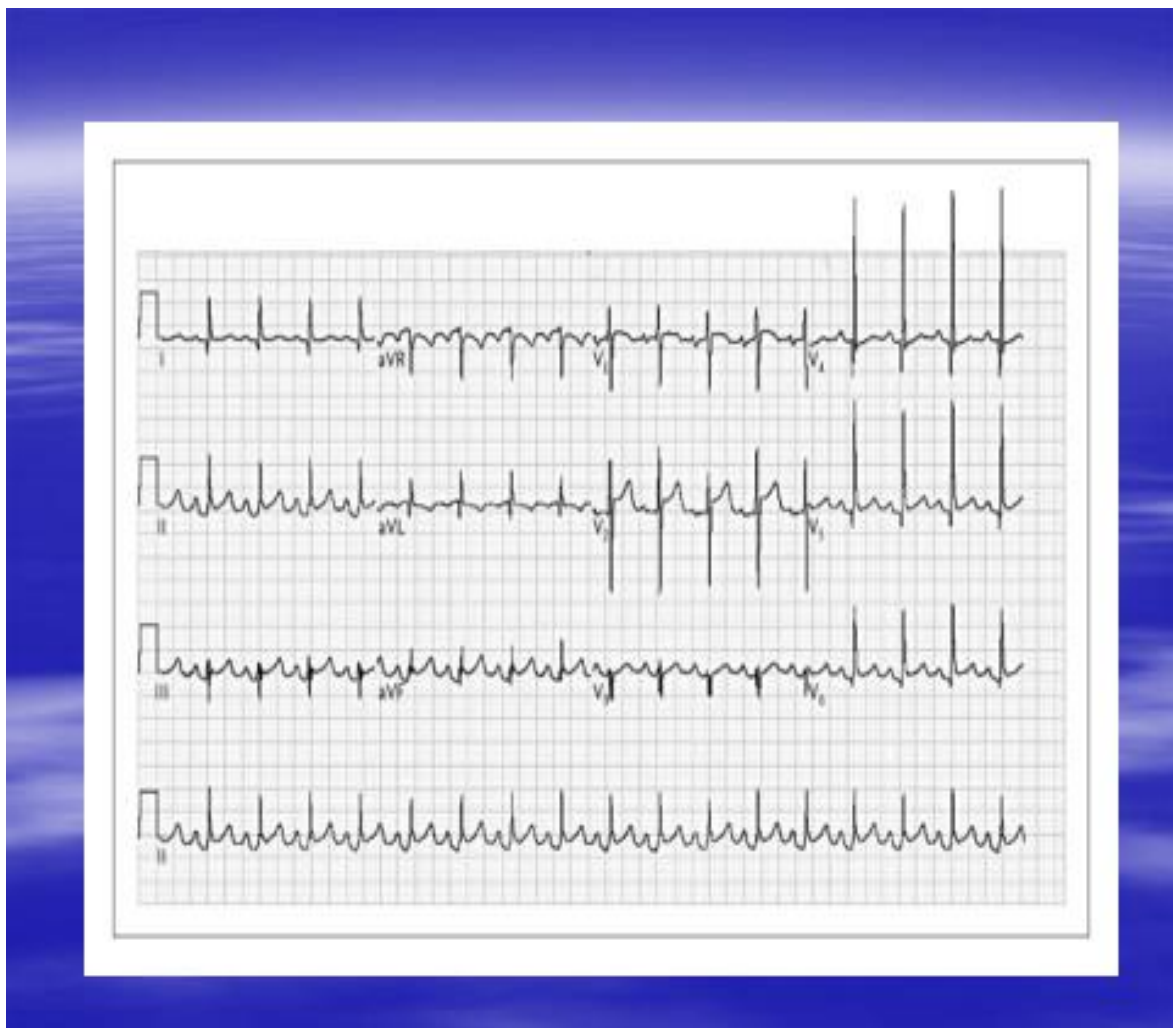Etiology

most frequent idiopathic or viral, tuberculous, acute IM, renal failure, previous radiotherapy, autoimmune diseases, previous cardiac operations, traumatic diseases, tumours

Clinical findings

chest pain, dyspnoea, pericardial friction murmur (pericarditis sicca – dry pericarditis)

ECG – elevation of ST segment, positive T waves, then depression of PR, then flatty T waves, inversion of T waves, finally normalisation



Chest X ray – heart dilation

ECHO CG – pericardial effusion

laboratory investigation – leukocytosis, increased erythrocyte sedimentation rate

diagnostic puncture of pericardium

Treatment

depending on cause

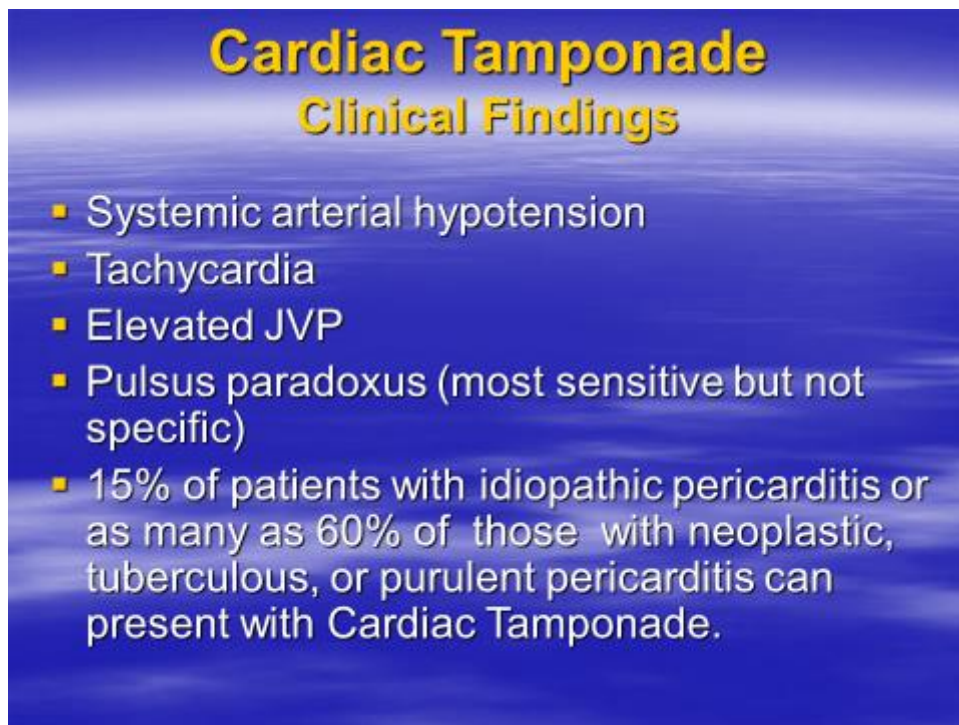
rest, no exercise

acetylosalicylic acid 4g daily, or NSA

corticosteroids

Complications:

heart tamponade, chronic pericarditis, constrictive pericarditis



Cardiac Tamponade
Clinical Findings

- Systemic arterial hypotension
- Tachycardia
- Elevated JVP
- Pulsus paradoxus (most sensitive but not specific)
- 15% of patients with idiopathic pericarditis or as many as 60% of those with neoplastic, tuberculous, or purulent pericarditis can present with Cardiac Tamponade.

Constrictive pericarditis

chronic pericarditis after previous acute pericarditis – limited diastolic filling of the heart. In etiology viral infections, radiotherapy, systemic autoimmune diseases

Clinical findings

increase of central venous pressure and pressure in the right atrium 10-15mm Hg

increase of filling pressures of the left and right heart on 15-30 mm Hg

heart failure, decrease of minute volume

Diagnostics: chest X ray (dilation of heart, lungs congestion, pericardial calcifications, ecg non specific findings - usually lower voltage, negative T waves, P mitrale, arrhythmias, ECHOCG – thickened pericardium, pericardial effusion, sometimes cathetrization of heart is necessary

Therapy

surgical resection

Specific forms of pericarditis

Viral pericarditis – Coxsackie, echoviruses, flu, infective mononucleosis, hepatitis B, mycoplasma pneumoniae – clinically acute pericarditis, duration usually 1-3 weeks, rare complications (myocarditis, relapse)

Tuberculous pericarditis – together with lung tuberculosis, hemorrhagic pericardial effusion, positive tuberculin test, DNA diagnostics

Bacterial pericarditis – traumatic etiology, or immunodeficient patients, perioperative (staphylococcal, pneumococcal, streptococcal, haemophilus influenzae, neisseria meningitidis)

Neoplastic pericarditis – usually hemorrhagic effusion – carcinoma of lungs, breast, Hodgkin lymphoma, leucaemia (cytological examination of effusion)

Post radiation pericarditis – appearance in 5-20 % of patients after radiotherapy, usually constrictive, therapy pericardiumectomy

Post infarction pericarditis – pericarditis epistenocardiaca – after first days of acute MI – chest pain associated with breathing – therapy not necessary, spontaneous remission

Postinfarction Dressler's syndrome – fever, pericardial effusion, frequently associated with pleuritis. Starts usually 3 weeks after acute MI – therapy aspirin, NSA or corticosteroids

Post pericardiotomy syndrome – after heart operations, etiology autoimmune, therapy aspirin, NSA, eventually corticosteroids